ECRONICON OPEN ACCESS

EC DENTAL SCIENCE
Case Report

The Partial All-on-4 Approach for Patients with Limited Posterior Bone Volume and Periodontally Compromised Teeth in the Maxilla: A Case Report

Eylül Berker Zenginer[2]*, Mustafa Yılmaz[1], and Onur Geçkili[2]

[1]*Deparment of Periodontology, Istanbul University, Istanbul, Turkey*
[2]*Deparment of Prosthodontics, Istanbul University, Istanbul, Turkey*

***Corresponding Author:** Eylül Berker Zenginer, Department of Prosthodontics, Faculty of Dentistry, Istanbul University, Istanbul, Turkey.

Received: November 10, 2025; **Published:** November 30, 2025

Abstract

The success of immediate loading protocols is contingent upon several key factors that must be meticulously evaluated prior to treatment. One of the most crucial factors is the quality and quantity of the available bone at the implant site, as this directly influences the primary stability of the implants. Sufficient bone density and volume are essential to support the immediate functional loads placed on the implants.

For patients presenting with anatomical challenges, such as inadequate bone in the posterior regions of the jaw, utilizing tilted posterior implants can be an effective strategy. This technique not only enhances the stability of the implant-supported prosthesis but also allows for the optimal use of the existing bone, aligning with the widely recognized All-on-4 treatment concept. By strategically placing tilted implants, clinicians can achieve favorable outcomes while minimizing the need for invasive procedures such as bone grafting, thus streamlining the treatment plan and reducing patient morbidity.

This clinical report details the application of a partial All-on-4 technique in a patient presenting with failing teeth on one side of the maxilla, while also addressing the future necessity of extracting periodontally compromised teeth on the contralateral side. The All-on-4 treatment modality has gained traction for its ability to provide patients with a fixed prosthesis supported by as few as four implants, optimizing functional and aesthetic outcomes while minimizing surgical intervention.

Keywords: *Immediate Loading; All-On-4; Dental Implant*

Introduction

Dental implants have emerged as a successful solution for restoring both complete and partial edentulous areas [1]. Advances in dental materials and technology now enable the provision of temporary prosthetic restorations during the same appointment, whether in cases of complete edentulism or when implants are placed immediately following tooth extraction [2]. The clinical success of immediate loading is influenced by multiple factors, including patient selection, bone quality and quantity, implant design and number, primary stability, occlusal loading, and the clinician's surgical expertise. Among these, primary stability is recognized as the most critical factor [3]. Defined as the biomechanical stability of the implant, adequate primary stability is essential, with successful osseointegration typically reflected by values of 70 ISQ or higher [4].

In cases involving the posterior severely atrophic jaw, extensive surgical bone augmentation procedures are often necessary to provide sufficient support for standard implants (10 - 12 mm in length and 3.5 mm in diameter). Augmentation surgeries carry risks such as increased patient morbidity, complications (e.g. infection and loss of graft material), higher costs, and longer treatment times [5]. To avoid such grafting procedures and effectively utilize existing bone, the use of angled implants has emerged as a promising alternative. Research indicates that there is no significant difference in success rates between angled and axially placed implants [6].

When residual bone volume is inadequate for traditional implant-supported rehabilitation, the All-on-4 concept provides an innovative solution. This approach employs four implants placed in the anterior region of completely edentulous jaws to support a provisional, fixed, and immediately loaded prosthesis. The two anterior implants are placed axially, while the two posterior implants are angulated distally to minimize cantilever length and facilitate the placement of prostheses supporting up to 12 teeth [7,8].

The partial All-on-4 technique is particularly advantageous for patients with failing teeth on one side of the jaw, allowing for the preservation of remaining healthy teeth while providing a stable prosthetic option. Hybrid prostheses composed of various materials are frequently utilized in the prosthetic superstructure [9-11]. In cases where screw access channels are not optimally positioned, Toronto prostheses are often preferred, even with angled abutments [12].

This clinical report details the application of a partial All-on-4 technique in a patient presenting with failing teeth on one side of the maxilla, while also addressing the future need for extracting periodontally compromised teeth on the contralateral side. The All-on-4 treatment modality has gained recognition for its ability to provide patients with a fixed prosthesis supported by as few as four implants, optimizing both functional and aesthetic outcomes while minimizing surgical intervention. The patient was successfully rehabilitated using the partial All-on-4 concept with immediate loading.

Case Report

A 64-year-old male patient with no significant systemic diseases presented to our clinic with pain and infections around existing implants. Radiographic and intraoral examinations revealed infection in the peri-implant tissues as well as in teeth 26 and 27 (Figure 1). Additionally, periodontal loss was noted in teeth 22 and 23, indicating the need for extraction of the infected teeth and those affected by periodontal disease. The removal of the implants in the regions of teeth 24 and 25 was also planned due to a buccal bone defect surrounding these implants (Figure 2).



Figure 1: *Initial panoramic radiograph depicting bone loss around the dental implant.*

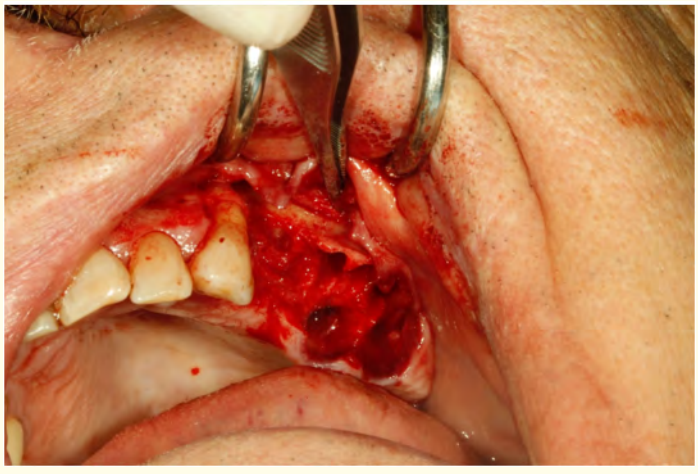

Figure 2: *Intraoral photograph showing periodontal loss in in the remaining teeth and extraction of the implants.*

Despite the absence of mobility in any of the teeth in the right quadrant, the decision was made to preserve the existing dentition for functional purposes. However, considering the patient's overall periodontal condition, it was anticipated that the remaining maxillary teeth might eventually be lost, necessitating a transition to a full-arch fixed prosthesis in the future. Therefore, a partial All-on-4 treatment approach was planned.

Surgical procedures

Under local anesthesia (Ultracaine DS Forte, Sanofi-Aventis, Frankfurt, Germany), the teeth in the maxillary left quadrant were extracted. The old implants in the regions of teeth 24 and 25 were removed using an implant removal kit (NeoFixture Removal Kit, Co., Korea). A Mode Rapid implant (13 mm length, 3.3 mm diameter) was placed parallel to the long axis in the region of tooth 22, while another Mode Rapid implant (16 mm length, 3.7 mm diameter) was inserted at a 45-degree angle in the region of tooth 24. Given that an insertion torque of ≥35 Ncm was achieved, immediate loading was performed. After implant placement, a 30-degree angled multi-unit abutment (Mode, Turkey) was attached to the tilted implant, and a straight multi-unit abutment was selected for the parallel implant. Following primary closure of the soft tissues, scan bodies were attached to the multi-unit abutments, and intraoral digital impressions of both the maxillary and mandibular arches were obtained. On the day of surgery, cantilever-free PMMA provisional prostheses were screwed to the multi-unit abutments (Figure 3).



Figure 3: *PMMA provisional prostheses screwed onto the multi-unit abutments.*

Prosthetic procedures

After a three-month healing period post-implant surgery, definitive prosthetic rehabilitation commenced (Figure 4). The provisional restorations were removed, and with scan bodies in place, the healed tissues were scanned intraorally for the final prosthesis. Due to the angulation of the implant in the region of tooth 22, the screw access channel emerged on the labial aspect. To address this and achieve an optimal aesthetic outcome, a partial Toronto design was selected for the definitive prosthesis (Figure 5).



Figure 4: *Radiograph taken with a provisional prosthesis after a 3-month healing period.*



Figure 5: *Intraoral photograph of the definitive prosthesis.*

Upon completion of the try-in procedures and verification of passive fit, the metal-ceramic restoration was torqued to 15 N/cm. The screw access channels were sealed with Teflon tape and composite resin (Figure 6).



Figure 6: *Follow-up radiograph of the patient.*

Discussion and Conclusion

The partial All-on-4 treatment approach for patients with periodontally compromised teeth on one side of the jaw offers an effective solution for restoring function and aesthetics. By extracting compromised teeth and placing implants in regions with adequate bone support, this method preserves remaining natural teeth, enhancing overall oral health.

This strategy not only addresses current periodontal issues but also anticipates future tooth loss, providing a proactive management solution. Ultimately, partial All-on-4 enhances patients' quality of life with a functional and aesthetically pleasing outcome while requiring ongoing monitoring of periodontal health for long-term success.

Bibliography

1. Albrektsson T., *et al*. "The long-term efficacy of currently used dental implants: A review and proposed criteria of success". *International Journal of Oral and Maxillofacial Implants* 1.1 (1986): 11-25.

2. Marković A., *et al*. "Immediate vs early loading of bone level tapered dental implants with hydrophilic surface in rehabilitation of fully edentulous maxilla: clinical and patient centered outcomes". *Journal of Oral Implantology* 48.5 (2022): 358-369.

3. Tettamanti L., *et al*. "Immediate loading implants: review of the critical aspects". *Oral and Implantology* 10.2 (2017): 129-139.

4. Payne AG and Solomons YF. "The prosthodontic maintenance requirements of mandibular mucosa and implant-supported overdentures: a review of the literature". *International Journal of Prosthodontics* 13.3 (2000): 238-243.

5. Del Fabbro M., *et al*. "Systematic review of survival rates for implants placed in the grafted maxillary sinus". *The International Journal of Periodontics and Restorative Dentistry* 24.6 (2004): 565-577.

6. Del Fabbro M., *et al*. "Tilted implants for the rehabilitation of edentulous jaws: a systematic review". *Clinical Implant Dentistry and Related Research* 14.4 (2012): 612-621.

7. Soto-Penaloza D., *et al*. "The all- on-four treatment concept: Systematic review". *Journal of Clinical and Experimental Dentistry* 9.3 (2017): e474-e488.

8. Bevilacqua M., *et al*. "The influence of cantilever length and implant inclination on stress distribution in maxillary implant-supported fixed dentures". *The Journal of Prosthetic Dentistry* 105.1 (2011): 5-13.

9. Sannino G and Barlattani A. "Straight versus angulated abutments on tilted implants in immediate fixed rehabilitation of the edentulous mandible: a 3-year retrospective comparative study". *The International Journal of Prosthodontics* 29.3 (2016): 219-226.

10. Maló P., *et al*. ""All-on-4" immediate-function concept for completely edentulous maxillae: a clinical report on the medium (3 years) and long-term (5 years) outcomes". *Clinical Implant Dentistry and Related Research* 14.1 (2012): e139-e150.

11. Ayna M., *et al*. "Comprehensive comparison of the 5-year results of all-on-4 mandibular implant systems with acrylic and ceramic suprastructures". *The Journal of Oral Implantology* 41.6 (2015): 675-683.

12. Scarano A., *et al*. "Zirconia crowns cemented on titanium bars using CAD/CAM: a five-year follow-up prospective clinical study of 9 patients". *BMC Oral Health* 19.1 (2019): 286.

Volume 24 Issue 12 December 2025
©All rights reserved by Eylül Berker Zenginer., *et al*.